

The Phytoestrogenic Potential of Yam Bean (*Pachyrhizus erosus*) on Ovarian and Uterine Tissue Structure of Premenopausal Mice

by Cicilia Novi Primiani

Submission date: 01-Nov-2019 08:56AM (UTC+0700)

Submission ID: 1204668482

File name: 16._JURNAL_BIOLOGY,_MEDICINE_AND_NATURAL_CHEMISTRY.pdf (1.11M)

Word count: 3081

Character count: 16825

The Phytoestrogenic Potential of Yam Bean (*Pachyrhizus erosus*) on Ovarian and Uterine Tissue Structure of Premenopausal Mice

Cicilia Novi Primiani

Biology Education, Mathematics and Science Faculty, IKIP PGRI Madiun
Jl. Setiabudi 85 Madiun, Tel. +62-351-462986, Fax. +62-351-459400

Author correspondence:
primianibiomipa@yahoo.co.id

Abstract

The use of estrogen hormone by public has significantly been improved either as prevention or treatment of disease. Menopausal issues in women are often treated using hormone replacement therapy. In regard to this, yam bean is found to contain genistein and daidzein compounds with a chemical structure that resembles estrogen hormone, therefore yam bean is categorized in the phytoestrogen group. The purpose of this study was to identify the potential of yam bean on ovarian and uterine histology of mice. This research employed a Completely Randomized Design of experimental research approach of one factor namely yam bean in three different dosage treatment: 0.3 g/kg, 0.6 g/kg, and 0.9 g/kg of yam bean for 24 days. The surgery and organ harvesting of ovary and uterus were conducted on Day 25 along with the making of histological preparat using paraffin method and Hematoxylin-eosin (HE) staining. The data was then analyzed descriptively. This research found that there were both secondary and tertiary follicle proliferation as the antrum contains some estrogen level. Meanwhile, the endometrial tissue of the uterus experienced uterine glandular proliferation. To conclude, yam bean was found to be a natural estrogen source.

Keywords: yam bean, isoflavone, phytoestrogen, ovarium, uterus, menopause

Introduction

Hormone replacement therapy (HRT) is an action which is conducted through giving estrogen hormone especially to women who experience some reduction in the estrogen hormone. HRT is usually undergone by women experiencing menopause. In particular, Estrogen Replacement Therapy (ERT) can also be used for conducting cardiovascular disease therapy (Stampfer et al., 1991 and Sourander et al., 1998), reducing the risk of osteoporosis (Grady et al., 1992 and Nurochmad et al., 2010), and reducing the symptoms of menopause (Barrett, 1998). The use of synthetic estrogen compound in a long term often gives negative impacts so that a natural alternative is needed to replace estrogen hormone.

Yam bean plant (*Pachyrhizus erosus*) as a tuber-legume crop, is categorised as a legume with the dissemination area of Sumatera, Java, Bali, Sulawesi and East Nusa Tenggara (Karuniawan & Wicaksana, 2006). People usually prefer to consume fresh yam bean either in the form of salad or rujak (Indonesian traditional fruit and vegetable salad dish). Yam bean extract is used in the cosmetics industry in whitening, compact powder, and moisturizer products. Yam bean contains isoflavone compounds with estrogen-like chemical structure (Wanibuchi, 2003; Abid, 2005; and Lukitaningsih, 2009). The chemical isoflavones structure resembles 17 β -estradiol and has the efficacy like estrogen hormone (Delmonte & Rader, 2006; Barlow et al., 2007) so that yam bean is also included in phytoestrogen group (Urasopon et al., 2008). The largest components of isoflavone are genistein and daidzein which are often

found in Fabaceae family, including *Pachyrhizus erosus* (Kang et al., 2006). *Pachyrhizus erosus* at least contain isoflavones such as, daidzein and genistein (Primiani, 2013), the analysis of PLC daidzein and genistein of yam bean is 110,454 mg/100 g and 165,530 mg/100 g respectively.

The chemical structure of genistein and daidzein can bind to estrogen receptor and compete with endogenous estrogen such that they may provide both estrogenic and anti-estrogenic effects (Adlercreutz, 1990; Griffiths et al., 1996; Adlercreutz and Mazur, 1997). Utilization of yam bean as phytoestrogen is not conducted much, a study by Nurrochmad et al., (2010) showed that providing yam bean extract of 400 mg/kg and 800 mg/kg dosage for 4 weeks to mice through ovariectomy could prevent bone fragility; phytoestrogen was then proven to be able to improve uterine mass (Ford et al., 2006). Meanwhile, Genistein affects on the increasing of weight of uterus by stimulating uterine endometrial thickening (Santell, 1997). Genistein dose 26,6 mg/day equivalent with human dose 0,625 mg/day within 6 months on monkey cause vaginal maturation (Marquez et al., 2012).

Research Methods

Research Design

The research was conducted using experimental research approach with a completely randomized design, the treatment was completed through providing grated yam bean in three different dosage: 0.3 g/kg, 0.6 g/kg, 0.9 g/kg. The observation is focused on the changes of ovarian and uterine tissue structure.

Tools and Materials

The research tools used in this study were: a gavage tube, plastic mice cages (50 x 30 x 20cm size), drinking bottles for mice, a digital scale (HM-200 brand), 1ml syringes with 3ml disposable needles (G23), an incubator, optical microscope, digital optilab camera microscope, a triple beam balance ohaus 700 series scale, analytical balance type HM-200 with the capacity of 210 grams and accuracy level of 0.1 mg, PR-50 microtome, surgical equipment, a surgical board, object glasses and lenses, glass beakers, spiritus lamp, a cube made of calendar paper, blender, flour sifter, a knife, a pipette, and a couple.

The research materials were yam bean obtained from Takeran village Madiun Indonesia, ovarian and uterine tissue, milk A granule for the mice food produced by PT. Charoen Pokphand Indonesia, husk, cotton, tissue paper, aqua destillata, water tap, paraffin, 0.9% physiological saline, bouin fixative solution, 50%, 70%, 90% and absolute alcohol, pure xylol, xylol-alcohol mixture, with xylol and alcohol comparison consecutively 1:3, 2:2, and 3:1, Li₂CO₃ solution, 1% HCl, 3% formalin, and haupt adhesive.

Animal Experiments

The experimental animals used were mice (*Mus musculus*) strain Balb/c female, in a good health condition, aged 12 months, 24 mice in total. Every mouse had an initial body weight ranging from 20-25 grams before treatment, the mice were kept in a cage located in the Biology Education IKIP PGRI MADIUN, Indonesia

Maintenance of mice and manufacture of test materials

The mice were placed in the mice cages, given food and drink ad libitum and acclimatized for 14 days prior to

induction treatment. The mice were maintained at the room temperature of ($\pm 27^{\circ}\text{C}$), relative humidity between 50-60% and 12 hour lighting cycle. Every day the mice were weighed as the basis for determining the provision of grated yam bean. The manufacture of grated yam bean as a research material was conducted through grating the yam bean using a grater. The amount of the yam bean was then weighed and complied with the amount given to the mice.

The provision of yam bean and manufacture of preparat of ovarian and uterine histology

The provision of yam bean was conducted through direct induction to the stomach using a gavage tube once a day for 24 days. The mice were then dislocated on the 25th day and dissected. The organ harvesting of their ovaries and uterus were then performed. The manufacture of the preparat of ovarian and uterine histology was completed using paraffin method in attempt to determine any ovarian and uterine tissue structure changes.

Data analysis

The ovarian and uterine tissue structure changes were analyzed descriptively based on the changes that happened in the ovarian follicle, myometrium layer, endometrium and uterine mucosa.

Results and Discussions

The results of observation on the ovarian tissue show³¹ that there were changes in the ovarian follicles (Figure 1).

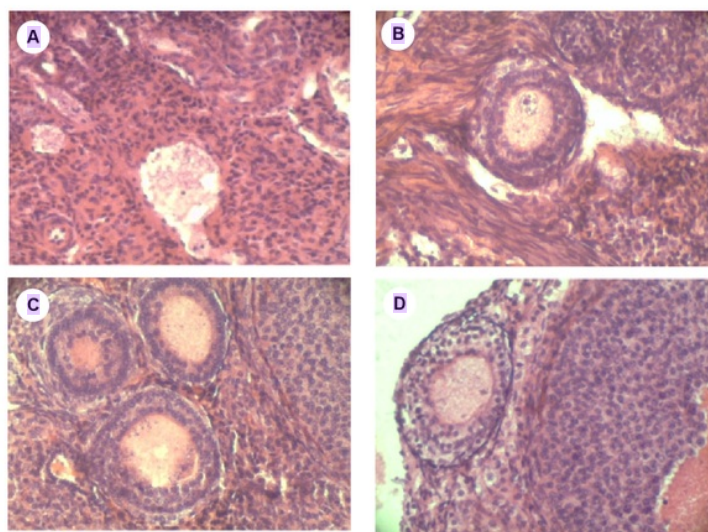


Figure 1. The ovaries of mice (*Mus musculus*); HE stained sections; 400x
Description: A. Control (P1); B. The dose of 0.3 g/kg (P2); C. The dose of 0.6 g/kg; D. The dose of 0.9 g/kg (P4).
A. Ovary with the control treatment, there are some corpus albicans.
B. Ovary with mature follicles and granulosal layer.
C. Secondary follicular proliferation, tertiary follicles begin to develop.
D. Tertiary follicles with follicular fluid.

The results of observation on the uterine tissue showed that there were changes in the uterus endometrium tissue (Figure 2).

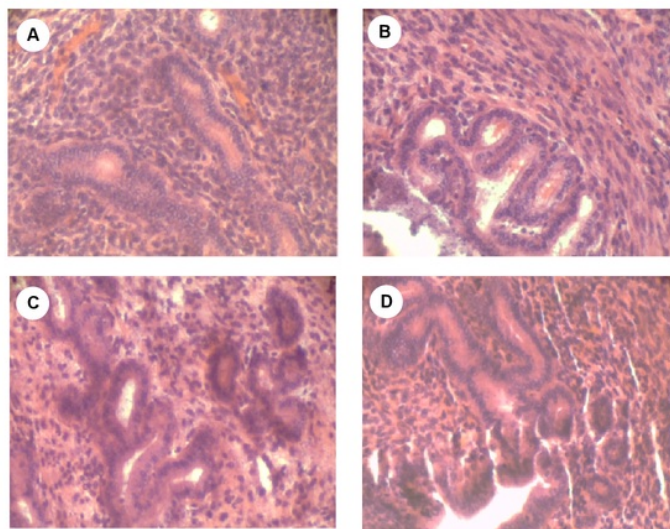


Figure 2. The uterus of mice (*Mus musculus*); HE stained; 400x Description: A. Control (P1); B. The dose of 0.3 g/kg (P2); C. The dose of 0.6 g/kgD. The dose of 0.9 g/kg (P4).
A. Uterine wall consists of tunica serosa, tunica muscularis and tunica mucosa.
B. Proliferation of tunica mucosa (uterus endometrium layer).
C. Proliferation of uterine glands in uterine endometrium layer.
D. Proliferation of endometrium and myometrium layers, proliferation of uterine glands.

The observation results of ovarian histology using hematoxylin-eosin (HE) staining are depicted in Figure 1. The control treatment (P1) shows follicles that experienced atresia (corpus albicans) and there is no indication of any primary follicle proliferation. The atresia folliculi phase shows histological features that represent disintegration in the form of fat drops and coarse granules in the ova (Figure 1A). In the ovary that is given grated yam bean of 0.3 g/kg dose, some follicles with a thick layer under the tunica albuginea occur and they have a unique characteristic that the ova contained do not have any vitellina membrane (Figure 1B). The ova are surrounded by layers of follicular cells which form granula layers on the more mature follicles afterward. In the provision of yam bean of 0.6 g/kg dose, secondary follicular growth takes place, the follicles are more egg-shaped (oval) and has been moving away from the cortex approaching the medulla ovary and forming a room that is filled with fluid (antrum) around the ova and the granulosa cells layer are coating it (1C). Liquid called liquor folliculi makes the follicles developed into tertiary follicles (apparent from the picture of ovary with 0.9 g/kg dose yam bean treatment) (1D).

Changes in the uterine tissue structure of the mice after being given grated yam bean are depicted in Figure 2. The results of observation on uterine histology with hematoxylin-eosin staining (HE) show that the uterine wall of the control treatment (P1) is relatively thick and formed in 3 layers: (1) tunica serosa or outer perimetrium in the form of connecting tissue that consists of a layer of mesothelium supported by a thin connective tissue, (2) tunica muscularis or myometrium is the thickest layer which is composed of smooth muscle tissue. Myometrium is the thickest tunica that consists of bundles of smooth muscle fibers which are separated by

connective tissue. The endometrium consists of epithelial siliata and non siliata as well as lamina propria or stroma endometrialis containing simple tubular glands (uterine glands) that are branched on the inside (near the endometrium) (Figure 2A).

The provision of grated yam bean of 0.3 g/kg (P2) causes endometrium and myometrium proliferation of the uterus, uterine luminal has been narrowing due to the epithelialization process. The proliferation of uterine glands of the uterus begin to exist despite the decrease of premenopausal period proliferation (Figure 2B). The grated yam bean provided to the mice at a dose of 0.6 g/kg (P3) dan 0.9 g/kg (P4) apparently causes proliferation of the uterine endometrium and myometrium layers and increases the number of uterine glands (Figure 2C and 2D).

Genistein and daidzein are categorised in isoflavone group with the chemical structure that is similar to estrogen hormone and able to work as estrogen. The similarity of the structure of genistein and daidzein demonstrate the ability to bind to estrogen receptors (Setchell & Cassidy, 1999). The decrease of ovarian follicles proliferation during the premenopause causes delays of tertiary follicle growth such that the secretion of estrogen hormone in the tertiary follicle antrum does not occur. The provision of grated yam bean can optimize the level of estrogen so that it is able to stimulate the development of primary follicles (primordial), secondary follicles, and tertiary follicles.

The provision of phytoestrogen during the premenopause period improves the secretion of estrogen hormone which later causes an increase in the endometrium proliferation and epithelial cells replacement to cover the surface of mucosa. Phytoestrogens have a similar structure to that of estradiol

which may also occupy estrogen receptors and lead to estrogen-like effects such as endogenous itself (Harrison et al., 1999). Myometrium may develop due to the phytoestrogens yam bean effect.

Genistein and daidzein in yam bean have an effect on uterine epithelium resulting in proliferation and cornification of epithelial cells as well as in the optimization of the secretion of estrogen. Decreased estrogen level in premenopausal and postmenopausal period, resulting in an excess amount of estrogen receptors that are not bound. Genistein and daidzein ability to bind to estrogen receptors called sex hormone binding globulin (HGB) serves to increase the production of steroid hormones and is responsible for binding estrogen and circulating it through the blood vessels (Setchell et al., 1998). Genistein as one of the isoflavone compounds has the effect of increasing the weight of the uterus by stimulating uterine endometrial thickening (Santell et al., 1997).

Decreased levels of endogenous estrogen in premenopausal period can cause the estrus phase to not occur, thus giving yam bean to premenopausal mice can stimulate the estrus phase. Genistein and daidzein as a group of phytoestrogens bind to estrogen receptors in the ovaries and uterus. The resulting response when estrogen levels are low is that the receptor and phytoestrogens binding will help in balancing estrogen levels. The function of estrogen in relation to reproduction is causing proliferation to occur and tissue in the reproductive organs to grow.

The use of natural materials as hormone replacement therapy in postmenopausal women is one of the alternatives that can be done to overcome the side effects. Component compounds contained in natural materials are very complex and often interact each other to provide a physiological effect (Ioannides, 2002 and Zhou et al., 2003). Multi component contained in herbal medicine is a compounds complexity that provides optimal effect (Lan and Jia, 2010).


Conclusions

Yam bean can be used as natural estrogen hormone source which can increase the proliferation and maturation of ovarian follicles and proliferation of uterine endometrial glands of the uterus in premenopausal period. Following up the need for estrogen therapy for premenopausal and postmenopausal women, it is necessary to study the effectiveness and safety ranging from experimentin on animals to humans, so its use as hormone therapy can be trustworthy.

References

- Abid, M. 2005. *Pharmacological Evaluation of Pachyrhizus erosus (L) Seeds for CNS Activity*. Disertasi, Bangalore: Rajiv Gandhi University of Health Science.
- Adlercreutz, H. 1990. Western Diet and Western Diseases: Some Hormonal Biochemical Mechanism and Associations. *Scandinavian J. Clin. Lab. Invest.* 50s 201:3-23.
- Adlercreutz, H., Mazur, W. 1997. Phyto-oestrogens and Western Diseases. *J. Anayls of Med.* 29:95-120.
- Barlow, J., Johnson, J.A., Scofield, L. 2007. Fact sheet on the phytoestrogen genistein. *NIEHS/NCI Environment Research Centers*.
- Barrett, C.E. 1998. Hormone Replacement Therapy. *BMJ.* 317:457-461.
- Delmonte, P., Rader, J. 2006. Analysis of isoflavones in foods and dietary supplements. *Journal of AOAC International*, 89(4):1138-1146.
- Ford, J.A., Clark, S.G., Walters, E.M., Wheeler, M.B., Hurley, W.L. 2006. Estrogenic Effects of Genistein on Reproductive Tissues of Ovariectomized gilts. *Anim Sci.* 84:834-842.
- Grady, D., Rubin, S.M., Petitti, D.B. 1992. Hormone Therapy to Prevent Disease and Prolong Life in Postmenopausal Women. *Ann Intern Med.* 117:1016-1037.
- Griffiths, K., Adlercreutz, H., Boyle, P. 1996. Nutrition and Cancer. Oxford: Isis Medical Media.
- Harrison, R.M., Phillippi, P.P., Swan, K.F., Henson, M.C., 1999. Effect of genistein on steroid hormone production in the pregnant rhesus monkey. *Society for Experimental Biology and Medicine*, vol. 222.
- Ioannides, C. 2002. Pharmacokinetic Interactions Between Herbal Remedies and Medicinal Drugs. *Xenobiotica.* 32:451-478.
- Kang, S., Chung, J.H., Lee, J.H., Fisher, G.J., Wan, Y.S., Duell, E.A. 2003. Topical N-acetyl cysteine and genistein prevent ultraviolet-light-induced signaling that leads to photoaging in human skin in vivo. *J Invest Dermatol.* 120:835-841.
- Karuniawan, A., Wicaksana, N. 2006. Kekerabatan genetik populasi bengkuang *Pachyrhizus erosus* berdasarkan karakter morfologi dan daun. *Bul Agrom.* (34)(2):98-105.
- Lan, K., Jia, W. 2010. An integrated metabolomics and pharmacokinetics strategy for multi-component drugs evaluation. *Current Drug Met.* 11:105-114.
- Lukitaningsih, E. 2009. The Exploration of Whitening and Sun Screening Compounds in Bengkuang Roots (*Pachyrhizus erosus*). Disertasi, Wurzburg: Bayerischen Julius Maximilians University.
- Marquez, S.R., Hernandez, H., Flores, J.A., Gutierrez, M.M., Duarte, G., Vielma, J., Rodriguez, G.F., Fernandez, I.G., Keller, M., and Delgadillo, J.A. 2012. Effects of Phytoestrogens on Mammalian Reproductive Physiology. *Tropical and Subtropical Agroecosystems.* 15 SUP 1:S129-S145.
- Nurrochmad, A., Leviana, F., Wulancarsari, C.G., & Lukitaningsih, E. 2010. Phytoestrogens of *Pachyrhizus erosus* Prevent Bone Loss in an Ovariectomized Rat Model of Osteoporosis. *Int. J. Phytomed.* 2:363-372.
- Primiani, C.N. 2013. *Dinamika Senyawa Daidzein Umbi Bengkuang (Pachyrhizus erosus) dalam Darah Serta Potensinya pada Tikus Betina*. The Proceeding of 10th National Seminar of Biology, Environment and their Educational Implementation. Biology Education Department, Faculty of Pedagogy, Sebelas Maret University, Surakarta. 6 July 2013. ISBN 978-602-8580-94-6. 3:502-510.
- Santell, R.C., Chang, Y.C., Muralee, G.N., William, G.H. 1997. Dietary genistein exerts estrogenic effects upon the uterus, mammary gland and the hypothalamic/pituitary axis in rats. *Nutr.* 127: 263-269.
- Setchell, K., Nechemias, L.Z., Cai, J., Heubi, J. 1998. Isoflavone content of instant formulas and the metabolic fate of these phytoestrogens in early life. *Am J Soc Clin Nutr.* 68:1453-1461.
- Setchell, K.D.R., Cassidy, A. 1999. Dietary Isoflavones: biological effects and relevance to human health. *J Nutr.* 129:758s-767s.
- Sourander, L., Rajala, T., Raiha, I., Mäkinen, J., Erkkola, R., dan Helenius, H. 1998. Cardiovascular and cancer death in

- postmenopausal women on estrogen replacement therapy (ERT). *Lancet*. 352:1965-1969.
- Stampfer, M.J., Colditz, G.A., dan Willett, W.C.1991. Postmenopausal Estrogen Therapy and Cardiovascular Disease. *N Engl J Med*. 325:756-762.
- Urasopon, N., Hamada, Y., Asaoka, K., Pongmali, U., dan Malavijitnond, S. 2008. Isoflavone content of rodent diets and its estrogenic effect on vaginal cornification in *Pueraria mirifica* treated rats, *Science Asia*, 34:371-376.
- Wanibuchi, H., Kang, J.S., Fukushima, S. 2003. Toxicity vs Benefecial Effects of Phytoestrogens. *Pure Appl Chem*. 75(11-12):2047-2053.
- Zhou, S., Gao, Y., Jiang, W., Huang, M., Xu, A., Paxton, J.W. 2003. Interactions of herbs with cytochrome P450. *Drug Metab Rev*. 35:35-98.



The Phytoestrogenic Potential of Yam Bean (Pachyrhizus erosus) on Ovarian and Uterine Tissue Structure of Premenopausal Mice

ORIGINALITY REPORT

6%

SIMILARITY INDEX

4%

INTERNET SOURCES

1%

PUBLICATIONS

2%

STUDENT PAPERS

PRIMARY SOURCES

1	uad.portalgaruda.org Internet Source	1%
2	www.scribd.com Internet Source	1%
3	docplayer.net Internet Source	1%
4	Submitted to Udayana University Student Paper	1%
5	Zeng-Ming Yang. "Temporal and spatial expression of leukemia inhibitory factor in rabbit uterus during early pregnancy", Molecular Reproduction and Development, 06/1994 Publication	1%
6	Submitted to University of Lancaster Student Paper	1%
7	lib.bioinfo.pl Internet Source	1%

J.M.D. Galama, M. Gielen, C.M.R. Weemaes.
"Enterovirus antibody titers after IVIG
replacement in agammaglobulinemic children",
Clinical Microbiology and Infection, 2000

Publication

<1%

Exclude quotes On

Exclude matches

< 10 words

Exclude bibliography On